

# R&R

## REWARD & RECOGNIZE

\*We apologize for  
missing any  
important news –  
please email  
updates to  
[Jennifer Fischahs](#)

MAY 24, 2019\*



COLLEGE OF MEDICINE TUCSON  
**Medical Imaging**

# PROMOTIONS/APPOINTMENTS

## Dr. Russ Witte



- Promoted to Professor, Medical Imaging, Optical Sciences & Biomedical Engineering

## Nilu Dorschner

- Elected to APCR board at AUR 2019
- Elected Chair of newly formed IR/DR ad hoc Committee

## Dr. Sarah Desoky



- Promoted to US Modality Director
- Appointed as Chair of the Society for Pediatric Radiology Thoracic Imaging Committee

## Dr. Charles Hennemeyer



- Promoted to Associate Professor, Medical Imaging

## Dr. Unni Udayasankar



- Promoted to Vice Chair of Quality and Safety

# 2019 GME SCHOLARLY DAY SHOWCASE WINNERS



Dr. Shahad Al Bayati

Many congratulations to our Residents who won [first prize](#) at the 2019 GME Scholarly Day Showcase on Tuesday, May 14<sup>th</sup>!



Dr. Michael Larson

## *Resident Clinical Posters*

**First Place** “The Outcomes of Simulation in Resident Breast Imaging Biopsy Techniques”

Shahad Al Bayati, MBBCh ; Martin Dufwenberg; Colin O'Brien; Brian Skidmore; Kimberly Fitzpatrick, MD and Marisa Borders, MD

## *Resident Research Posters*

**First Place** “Towards Optical Biopsies: Developing an Optical Biopsy ‘Stain’”

Michael Craig Larson, MD, Jennifer Barton, PhD and Urs Utzinger, PhD



# WELL-DONE, DR. ARIF



Hina Arif-Tiwari, MD

Congratulations on the receipt of a CROC (Clinical Research Oversight Council) grant for further research on prostate fusion. The \$57,525 Arizona Cancer Center grant award will support research for 2 years. This is the second grant on fusion Bx. The AZCC awarded the first grant for fusion imaging (ACS-IRG) in 2017.

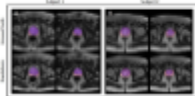
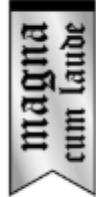# AWARDS

## Dr. Maria Altbach and her colleagues received Magma Cum Laude awards in presentations at the 2019 ISMRM



Maria Altbach, PhD

13:54 0833.




Lavanya Umapathy, MSc

### A Cascaded Residual UNET for Fully Automated Segmentation of prostate and peripheral zone in T2-weighted 3D Fast Spin Echo Images

Lavanya Umapathy, Wyatt Unger, Faryal Shareef, Hina Arif, Diego Martin, Maria Altbach, Ali Bilgin

Multi-parametric MR images have been shown to be effective in the non-invasive diagnosis of prostate cancer. Automated segmentation of the prostate eliminates the need for manual annotation by a radiologist which is time consuming. This improves efficiency in the extraction of imaging features for the characterization of prostate tissues. In this work, we propose a fully automated cascaded deep learning architecture with residual blocks (Cascaded MRes-UNET) for segmentation of the prostate gland and the peripheral zone in one pass through the network. The network yields high dice scores (mean=0.91) with manual annotations from an experienced radiologist. The average difference in volume estimation is around 6% in the prostate and 3% in the peripheral zone.

0462.



Mahesh Keerthivasan, PhD

### Efficient T2 Mapping of the Carotid Artery using a 3D Stack-of-Stars Variable Flip Angle TSE Pulse Sequence

Mahesh Bharath Keerthivasan, Kevin Johnson, Ali Bilgin, Craig Weinkauff, Maria Altbach

We present a radial stack-of-stars TSE pulse sequence with an efficient radial view ordering and optimized refocusing flip angles for 3D T2 mapping of the carotid artery. The technique provides excellent anatomical coverage within clinically acceptable times. The short acquisition time makes the technique less susceptible to motion. Performance of the technique is evaluated using phantoms and in vivo experiments.

R & R



COLLEGE OF MEDICINE TUCSON  
Medical Imaging



# AWARDS



Dorothy Gilbertson, MD

## 2019 College of Medicine Faculty Mentoring Award Recipient

Faculty were asked to submit letters of nomination for their mentors indicating the types of mentoring that their mentor provided and how their mentor has contributed to their success.

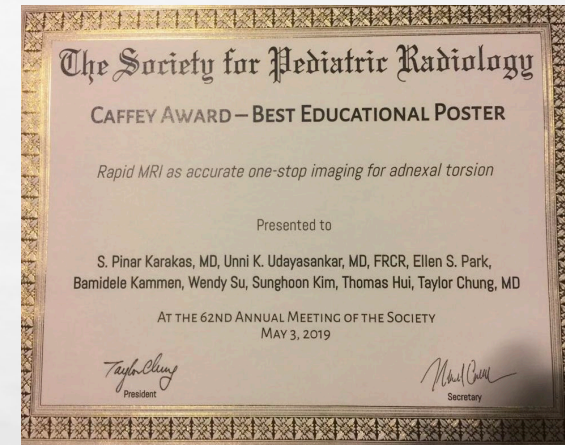Twenty-two nominations were received this year. The letters underwent rigorous review by the DCFA and ultimately seven awardees were chosen.

“Dr. Gilbertson has opened many doors for me in the department as well as multiple regional and national societies.”



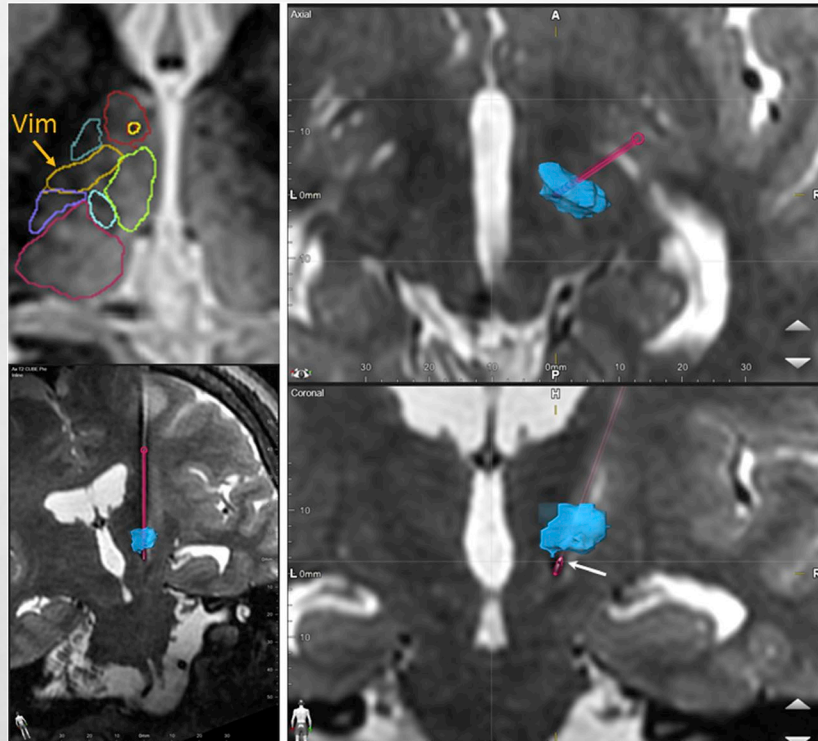
Unni Udayasankar, MD

## SPR (Society of Pediatric Radiology) Caffey Award



Dr. Udayasankar collaborated with pediatric radiologists from UCSF Oakland and the Cleveland Clinic

# RESEARCH



## NeuroImage

Volume 194, 1 July 2019, Pages 272-282

### Thalamus Optimized Multi Atlas Segmentation (THOMAS): fast, fully automated segmentation of thalamic nuclei from structural MRI

Jason H. Su <sup>a</sup>, Francis T. Thomas <sup>b</sup>, Willard S. Kasoff <sup>c</sup>, Thomas Tourdias <sup>d</sup>, Eun Young Choi <sup>e</sup>, Brian K. Rutt <sup>f</sup>, Manojkumar Saranathan <sup>b, g, h, i</sup>



Manoj Saranathan, PhD

Application to deep brain stimulation (DBS) electrode placement—pre-operative 3T wmm MP-RAGE images acquired on a patient who underwent traditional DBS surgery using awake physiologic guidance were segmented using THOMAS (top left). The right top and bottom panels show axial and coronal planes of post-operative 1.5T T2 cube images with the volume rendered vim label overlaid after registration (blue). The segmented DBS electrode is shown in pink with the bottom left image showing the full path (“electrode” view). The active contact point (second from the end) is depicted using the white arrow and is at the inferior margin of the vim

<https://doi.org/10.1016/j.neuroimage.2019.03.021>

R & R



COLLEGE OF MEDICINE TUCSON  
Medical Imaging



PUBLISHED

**Dr. Hennemeyer,  
Dr. Woodhead  
& Dr. McGregor:  
*FIRST* in-Human  
Gallbladder  
Cryoablation**

Article in Press

## First in-Human Gallbladder Cryoablation in a Patient with Acute Calculous Cholecystitis Initially Treated with a Cholecystostomy Tube

[Hugh McGregor](#), MD<sup>a,\*</sup>, [Gregory Woodhead](#), MD<sup>a</sup>, [Miles Conrad](#), MD<sup>b</sup>, [Andrew Tang](#), MD<sup>c</sup>, [David Ruiz](#), MD<sup>a</sup>, [Abdul Khan](#), MD<sup>a</sup>, [Charles Hennemeyer](#), MD<sup>a</sup>

✱ PlumX Metrics

DOI: <https://doi.org/10.1016/j.jvir.2018.12.011>

⊕ [Article Info](#)

[Abstract](#) [Full Text](#) [Images](#) [References](#)

### Abstract


A 71-year-old poor surgical candidate with acute calculous cholecystitis was initially managed with cholecystostomy tube drainage for 28 days. He subsequently underwent gallbladder cryoablation under moderate sedation with 3 cryoprobes and 2 separate 10-8-10 freeze-thaw cycles targeting the gallbladder neck/body and fundus followed by cholecystostomy tube removal. He was discharged 1 day after ablation. Magnetic resonance and hepatobiliary iminodiacetic acid scan 1 month postablation demonstrated a thick-walled, distended gallbladder and no filling of the cystic duct. Magnetic resonance 3 months postablation demonstrated retraction of the gallbladder wall with luminal collapse. The patient denied any pain after discharge and is asymptomatic 3 months after ablation.



# PRESENTATIONS



Dr. Gilbertson presenting  
at ARRS 2019



Dr. Becker presenting at  
ARRS 2019



- Dr. Kubal presented a course entitled “Global Anoxic Injuries” as one part in a four lecture series on Emergency & Trauma I (IC205 )
- Dr. Kuo gave two presentations at ARRS 2019
- Dr. Udayasankar presented at ARRS and the Society of Pediatric Radiology annual Meeting
- Dr. Becker and Dr. Gilbertson (pictured) presented at ARRS 2019





Come see current **Resident** and **Fellow** research **Present your findings!**

# Medical Imaging Research Day

Prizes awarded to top display





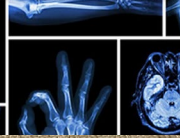




**May 21**

**Lunch Will be Served!**

All electronic presentations and posters from July 1, 2018-June 30, 2019 are welcome.

Sign up with **Melissa** in Room 1343 or via Email [mruiz@radiology.arizona.edu](mailto:mruiz@radiology.arizona.edu) by **April 23<sup>rd</sup>**.

**Tuesday, May 21**  
**11:30 AM- 1:00 PM**  
**HSIB**



R & R



COLLEGE OF MEDICINE TUCSON  
**Medical Imaging**



# DR. HARRISON BARRETT'S PARTY

...was a tremendous success!

Thanks to all who attended his  
retirement party festivities.



Dr. Barrett is pictured with  
his daughter, Mindy and  
wife, Cathy



Dr. Barrett is the  
2019 co-recipient  
of the Inaugural  
***SPIE Harrison H.  
Barrett Award in  
Medical Imaging***  
(with Arthur E.  
Burgess,  
Charles E. Metz  
and Robert F.  
Wagner)